

# Managing high-output stomas:

## Module 3 of 3

**Rebecca Slater and Simon Gabe**

### Abstract

Enterocutaneous fistulae (ECF) and high-output stomas are challenging to manage, owing to the large volume of loss that may result in severe dehydration, electrolyte imbalances, malnutrition and sepsis. It is imperative that this group of patients receive adequate nutrition, as malnutrition and sepsis are the leading cause of death. Treatment is complex and based on various situations, treatment can be medical/conservative management or surgical. Depending on the site of the fistula and the length of residual intestine contributing as the cause of a high output stoma with the nutritional status of the patient, clinicians have to decide whether parenteral nutrition (PN) or enteral nutrition (EN) should be established. As previously discussed in module 1 and 2 (Gabe, 2013; Gabe and Slater, 2013) the theme of nutritional management and appliance/accessory selection to manage patients with ECF and high output stomas was outlined. The aim of providing an understanding of the nutritional needs and the practicalities of maintaining appliance adherence, and in turn, a reduction in the breakdown of the peri-stomal skin was described. Module 3 aims to provide understanding for the reader that may encounter patients undergoing surgery for the management of their ECF or high-output stoma. Lastly it was felt necessary to discuss the subject of intestinal transplantation. This complex surgical option is not available to all patients with intestinal failure and only undertaken at a couple of recognised centres. The process of referring patients that are deemed suitable for intestinal transplantation will be addressed and what the surgery entails with long-term outcomes and the quality of life for the patient.

**Key words:** Intestinal failure ■ Intestinal transplantation  
■ Intestinal continuity ■ Postoperative nutrition ■ Fluid balance

Fleming and Remington (1981) first defined intestinal failure (IF) as a reduction in functioning gut mass below the minimum amount necessary for adequate digestion and absorption of nutrients. Although, as time has gone by, later authors have described IF as an acute or chronic condition when there is inadequate functional intestine present to maintain health with ordinary intake of food and drink (Forbes, 2007), or, that it is failure of the intestinal tract to maintain hydration and electrolyte balance in the absence of supplements (Nightingale, 2001).

Rebecca Slater is Colorectal and Stoma Nurse Specialist,  
Simon Gabe is Consultant Gastroenterologist and Senior Lecturer,  
St Mark's Hospital, London

IF, often still referred to, as 'short bowel syndrome' remains one of the most difficult gastrointestinal conditions to manage. The term 'short bowel syndrome' is misleading, this conjures up an image of an intestine that has been shortened through resection. It is now recognised that the term 'intestinal failure' provides a more accurate description.

As IF is the reduction in intestinal absorption macronutrient and/or water and electrolyte supplements are needed to maintain health and/or growth (Nightingale, 2001). Without such treatment under-nutrition and/or dehydration will result (Nightingale, 2003). The severity of IF can be graded according to the type of nutritional support required to maintain a patient (*Figure 1*). There are four aims in the management of patients with IF:

- To provide the nutrition and/or water and electrolytes necessary to maintain health and/or growth
- To reduce the severity of IF
- To prevent and treat complications, including those related to the underlying disease, IF itself or the treatments
- To achieve a good quality of life.

### Type 1 intestinal failure

Type 1 IF is an acute, or temporary, condition that is potentially reversible and the most commonly encountered. Often these are patients that are within the perioperative period. Carlson (2003) stipulates that the single most common diagnosis of Type 1 IF requiring surgical treatment is Crohn's disease associated with intestinal fistulas. Carlson goes on to state that this is probably either as a consequence of the disease, or a complication of the surgical treatment.

Within the groups of surgical patients with Type 1 IF present, many of the initial problems resolve when the trauma imposed due to surgery postoperatively subsides, and so, intestinal function returns, along with the normal absorption of nutrients and electrolytes.

In practice, virtually all patients with Type 1 IF will require nutritional support. Within the simple cases that are associated with postoperative intestinal dysfunction, (postoperative ileus), this support is only necessary until the return of normal digestive function. Patients with high-output fistulae within the proximal gastrointestinal tract will require nutritional support until the fistula has spontaneously closed or successfully corrected with surgery (Scripcariu et al, 1994).

### Type 2 intestinal failure

Type 2 or chronic IF is less common and most patients will have a short bowel (Nightingale, 2001). Type 2 will occur in a number of cases, owing to an intestinal myopathy (e.g. systemic sclerosis

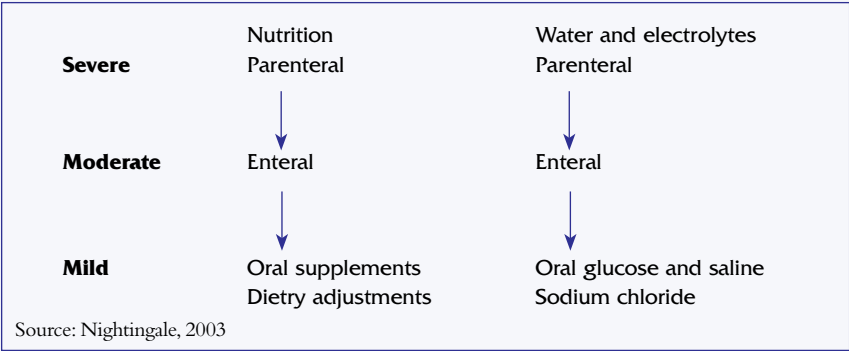


Figure 1. Nutritional requirements

Table 1. Intestinal failure	
The term short bowel syndrome is appropriate for:	
■ Anatomical short bowel	■ High output fistula
■ Functional short bowel	■ High output stoma
The key determinant is whether a patient can maintain a positive fluid or nutritional balance	
Anatomical	Functional
■ <100 cm small bowel to end stoma or to an enterocutaneous fistula	■ >200 cm small intestine with a malabsorptive process (e.g. refractory sprue, chronic intestinal pseudo-obstruction, congenital villus hypoplasia)
■ <50 cm small bowel with colon in continuity	

or visceral myopathy) or severe cases of inflammatory bowel disease resulting in multiple resections of the intestinal tract (a number of the patients encountered will have a jejunostomy).

Patients with Type 2 IF will require long-term nutritional support, which is inevitably parenteral nutrition, in order to remain well-nourished and maintain life. Not all patients with enterocutaneous fistulae (ECF) are classified as having Type 2 IF. For those that are, it will be owing to the patient's suitability/fitness to undergo further surgery, the remaining length of functioning intestine, the anatomy of the fistula, and the patient's ability to maintain a safe nutritional status and electrolyte balance on oral intake long-term. Table 1 illustrates the classification of IF.

Keighley and Williams cited in Burch (2004), state that simple fistulae have a better prognosis than complex fistulae

in a sense that they are more likely to heal spontaneously. Berry and Fischer (1996) proposed that it is estimated approximately 75–85% of ECF form after an operation as a result of bowel injury, inadvertent enterotomy and/or anastomotic leakage. Berry and Fischer (1996) go on to stipulate that in the remaining 15–25% of instances, ECF form spontaneously secondary to underlying pathology. Fistulae formation is more commonly associated with surgery in the presence of malignancy or inflammatory bowel disease (IBD) (Berry and Fischer, 1996).

Surgical management of ECF and high-output stomas

The most obvious surgical strategy for management of IF induced by ECF and high output stomas is to simply restore the intestinal continuity (Carlson, 2003). A variety of surgical procedures have been undertaken, all aimed at optimising the function of the residual intestine, increasing intestinal length and, in particular, slowing transit.

Cases of surgical management have not all proved to be beneficial and many cases of surgical management for ECF with an underlying diagnosis of Crohn's disease have proved difficult to manage surgically. Eighteen percent of these cases will require re-operation due to fistulation within the first year of initial surgery (Levy et al, 1988).

The timing of corrective surgery in relation to the initial operation(s) is important as it affects the incidence of further complications (Levy et al, 1988). Delaying surgery will also give rise to the opportunity to correct metabolic and nutritional deficiencies. Unpublished observations from St Mark's Hospital indicate that successful closure of an ECF is associated with low initial fistula output and an absence of comorbidity.

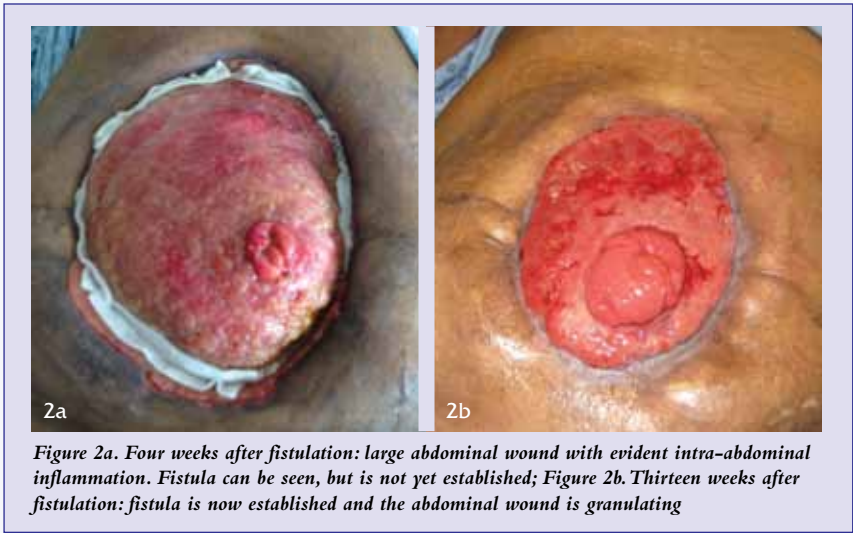
The prolapsing of intestine that has fistulated, otherwise known as the fistula becoming established, is an indicator that surgery to repair is now a safe option. When the inflammation intra-abdominally has settled and the intestine is no longer adhered together into what can be a complex mass of intestine and is soft and mobile the exposed intestine that is the fistula becomes soft, moist, extremely mobile and prolapses into a more pronounced 'spout' of intestine (Figure 2a and Figure 2b).

The initial imperative is stabilisation of the patient. Stabilisation should focus on correction of fluid depletion and any electrolyte imbalance (Levy et al, 1988).

Surgery can put patients at risk of malnutrition, due to starvation, physiological stress response and the subsequent increase in metabolic rates. Gastrointestinal surgery can pose additional problems as it limits dietary intake postoperatively. It is also associated with tissue breakdown and impaired organ function which leads to increased morbidity and longer periods of hospitalisation. This explains why patients who are already not optimal for such extensive intestinal surgery, such as those with complex ECF and high-output stomas with reduced length of residual intestine, pose such a risk during their early postoperative recovery.

The standard postoperative surgical care is implemented to this group of patients. The placement of a urinary catheter, central venous line with peripheral access if possible, a naso-gastric tube and abdominal drains is normal practice.

All patients should be kept on a strict fluid balance





management and this should be recorded and monitored hourly with 12-hourly evaluations and 24-hourly balance comparisons. Monitoring of the patient's weight, coupled with analysis of blood results and urine sodium twice a week should indicate how stable a patient is and what treatment plan would be suitable. It is imperative that all members of the multidisciplinary team are aware of the surgical technique undertaken to repair the ECF and restore the intestinal continuity. The surgical team will monitor the effect of the surgery and daily recovery with the audition of bowel sound presence (using a stethoscope) and daily reviews of blood results and fluid balance. The gastrointestinal and nutrition team will monitor the patient daily for the requirement of intravenous nutritional replacement/balance, and the daily loss or gain of fluid volume, which may indicate dehydration or overload of intravenous fluid replacement.

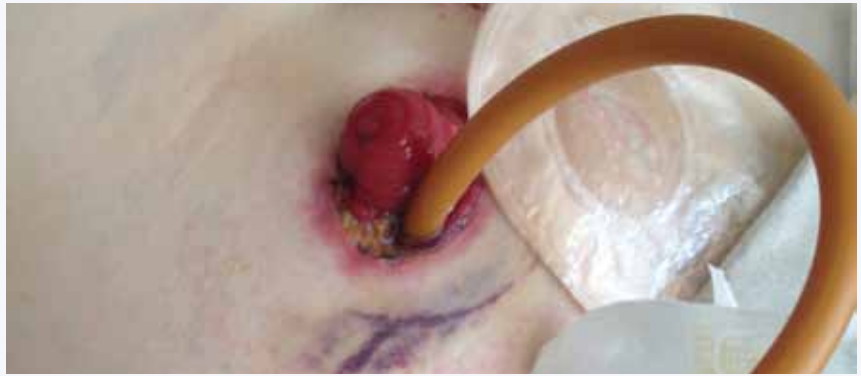The postoperative abdomen will be extremely acute for around 7–10 days postoperatively, owing to the massive inflammatory response that naturally occurs following invasive and extensive surgery, along with the shift of fluid within the cellular space, contributing to sometimes gross distension of the abdomen with delayed passage of flatus and faeces. It is imperative at this stage that the patient is observed for signs of sepsis secondary to infection or even possibly an anastomotic leak.

All patients that have undergone restoration of intestinal continuity for complex ECF or high output stomas will have a nasogastric tube in situ. The length of time that the nasogastric tube will remain in situ depends on the length of time the intestine takes to recover from the stress imposed by invasive surgery. Invariably the nasogastric tube will remain until the patient is passing flatus and oral fluids are being tolerated. With the placement of the nasogastric tube, it is possible to monitor the patient for a delayed ileus, but more importantly to reduce the pressure placed on the intestine by the constant flow of gastrointestinal secretions produced. The nasogastric tube should be placed on free drainage and aspiration of the tube should be implemented 4 times hourly, unless the patient experiences nausea and hiccups in between aspiration of the tube. As the intestine recovers from the effects of surgery, the output from the nasogastric tube will decrease and the passage of faeces should occur.

In some cases of repair of ECF, where multiple small bowel resections are undertaken with multiple anastomosis a temporary high-output stoma is created. The management of such stomas and the choice in appliances and nutritional management was discussed in Module 1 (Gabe and Slater, 2013). Fistuloclysis (distal feeding) is implemented to prepare and optimise the intestine and to improve the surgical outcome of restoring intestinal continuity regularly in the author's practice (RS) (*Figure 3*).

### **Fistuloclysis to improve surgical outcome**

In selected patients, it may be possible to use the intestinal tract for nutritional support, despite the presence of a fistula. In cases where there is mucocutaneous continuity at the site of an intestinal fistula (which indicates that spontaneous closure will not occur), the intestine distal to the fistula can be intubated and used to deliver enteral feed. This is a technique



*Figure 3. Temporary loop jejunostomy following repair of ECF with the implementation of fistuloclysis*

termed 'fistuloclysis' (Teubner et al, 2004)).

Many studies from central Europe have looked into the technique of fistuloclysis, whereby the technique involves re-infusing the upper gastrointestinal contents. Early studies used the re-infusion of the bowel effluent from the proximal limb of the fistula. However, this method proved to be unpopular. It is reported that the patient's nutritional needs were met with a polymeric feed, not requiring the re-infusion of chime. As Carlson (2003) states, this will only be effective provided that the patient has a sufficient length (greater than 0.75 m) of healthy small intestine available distal to the site of the fistula.

The criterion used for fistuloclysis is that set out by Salford Royal Hospital, Manchester. Salford Royal Hospital has been successful in a number of patients in implementing fistuloclysis on some groups of patients with ECF. They have developed an information and guidance booklet for both patients and health professionals seeking to implement fistuloclysis. The booklet is informative, descriptive and very easy to follow. It is recommended for those wanting to find out more about the practical aspects to enteroclysis and fistuloclysis.

Fistuloclysis is a form of enteral feeding, although uncommon, it enables the bowel below the fistula to absorb nutrients that are not absorbed up to the point of the fistula (Sica and Birch, 2007). Teubner et al (2004) suggest that this technique has failed to gain popularity, possibly owing to its complexity and aesthetic considerations. In this study, successful fistuloclysis was defined as the ability to maintain or increase body weight and normal serum biochemistry, without the need to resume parenteral nutrition or parenteral fluid therapy until definitive reconstructive surgery can be undertaken. Although fistuloclysis is not feasible for all patients with ECF, for those that are eligible, the method appears to be an acceptable and safe method of maintaining and improving nutrition status (Ham et al, 2007).

Ham et al (2007) suggest that it is not known if the presence of a feeding tube delays the spontaneous healing of an ECF. Although it would be inappropriate to cannulate the tract of an ECF if spontaneous closure was a possibility. The finding of intestinal mucosa on the surface of the skin or embedded within the granulation tissue of a wound healing by secondary intention does suggest that spontaneous closure would not occur (Teubner et al, 2004).



**Box 1. Instructions for setting up and administering fistuloclysis distal feeding**

1. Place the blue cone into the stoma bag through the opening
2. Feed the blue cone down up to the desired position, which is usually on the lower end of the bag
3. Pierce the blue cone through the film of the stoma bag from the inside to the outside
4. Take the white rubber cone and put it on top of the blue cone
5. Press the two points firmly together so that they stick. Now remove the blue cone
6. Cut a small piece off the end of the white cone to create a small hole
7. Take the white connector/adaptor and insert it into the gastrostomy feeding tube
8. Cut the cap off the gastrostomy feeding tube to avoid it catching
9. Manoeuvre the tube into the stoma bag, through the opening, towards the cone system
10. Attach the male-to-male luer-lock adaptor to the white connector in the cone
11. Feed the white connector/adaptor into the white rubber cone so that the ends are level
12. Attach the end of the giving set
13. The patient now connects the feeding giving set to the stoma appliance

For detailed instructions on how to set up the equipment with detailed pictures an easy to follow booklet can be obtained from the Hope Hospital, Salford, Manchester

**Accessing distal intestine**

The total length of small intestine above and below each fistula must be determined using contrast radiology (Teubner et al, 2004). After the integrity and length of the small intestine beyond the most distal fistula opening has been confirmed, the fistula is intubated with a balloon retention gastrostomy tube. The catheter is then advanced by a depth of 5–10 cm under radiological control and the catheter balloon is inflated with 5 ml of water. Once the catheter is inserted, it is secured with a single suture. The fistula is enclosed within a stoma appliance that is linked to a universal catheter access port. This allows the collection and measurement of proximal enteric content, while the enteral feed is infused into the fistula.

**Enteral feed and administration**

Most feeds are commenced at an initial rate of 30 ml/h and the rate of the infusion is increased by up to 20 ml/h each day dependent on the patient's ability to tolerate the feed. The feed is increased daily, until a target rate of 90 ml/h is reached.

The majority of feeds chosen for fistuloclysis are with a high content of medium-chain triglycerides. It is believed that these are easily absorbed in the small intestine (Teubner et al, 2004). However, often it is a matter of trial and error to see which feeds are better tolerated by the patient. There is also a good argument for using a partially hydrolysed feed that may be better absorbed by the distal small bowel.

At St Mark's the author (Slater) and colleagues are also implementing bolus enteroclysis and fistuloclysis instead of continuous feeding enteroclysis and fistuloclysis. The rationale is different. Instead of trying to deliver enteral nutrition to the level of meeting nutritional requirements

for a patient, enough luminal nutrition to 'feed the intestinal mucosa' is delivered. With that concept, small amounts of enteral nutrition can be delivered (100–200 ml/day). Here the purpose is to prevent the distal bowel from atrophying. This is done in patients who are awaiting re-continuity surgery and this appears to maintain the distal bowel in a better state for subsequent anastomosis. However, at the moment the benefit is subjective and this technique needs to be studied properly in a series of patients.

**Postoperative bowel function following restoration of intestinal continuity**

Despite the successful repair of an ECF, or the closure of a high-output stoma, for most patients urgency, erratic bowel function and high volume loss will remain a permanent problem following restorative surgery.

Initially the frequency and volume loss of faeces is very high following restorative surgery and starts to settle over a period of 6–12 weeks. The initial cause for urgency and frequency is due to the watery consistency of the faeces. The introduction of a low-fibre, high-starch base diet with the control of oral fluids will aid the thickening of the faecal volume and reduction in time to defecation.

However, it is not always the case for this group of patients. For most patients that have undergone restoration of intestinal continuity, they have lost a high proportion of their small intestine and as a result cannot absorb essential electrolytes and nutrients. For most patients this is normal as they have lived with a high-output stoma or ECF for at least 6 months and had to adjust their diet and fluid intake, as well as their personal life, in order to manage their faecal loss.

The option of surgery to repair the ECF or close the stoma often leads to the patient expecting their bowel function to return to 'normal' or to what it was before the event that caused them to require nutritional and nursing input to manage their high output ECF or stoma. Patients often presume that they will return to a varied diet, without the need to monitor their fluid intake or bloods at regular intervals. It is imperative that the gastroenterologist and stoma care nurse prepare the patient preoperatively and address his or her postoperative expectations.

**Management of bowel function**

A number of therapies can be implemented to reduce the urgency and frequency of faeces and to improve the patient's ability to control defecation, and thus maintain their quality of life. Before surgery, anal physiology is advisable to assess the tone of the sphincters and the patient's ability to defer defecation for a prolonged period of time. Anal physiology, or biofeedback as it is widely known, is useful in gathering essential information that will allow us to mentally prepare our patients prior to surgery. With the results gained from undertaking biofeedback, it can be observed which patients may require implementation of further therapies and pelvic floor exercises to increase faecal continence and, importantly, highlight which patients may not be continent of faeces.

As most patients experience permanent urgency and frequency following restorative surgery the implementation of pharmacological therapies with biofeedback can be useful. As



discussed in Module 1 (Gabe and Slater, 2013), the regimen of implementing loperamide and codeine phosphate to reduce and thicken a high output can also be implemented following surgery to restore intestinal continuity as patients continue to experience a high, loose output.

### Small bowel intestinal transplantation

Small bowel transplant is considered when patients with intestinal failure develop complications from total parenteral nutrition (TPN).

The first operation performing small bowel transplantation was undertaken in Minnesota by a surgeon called Mr Lillehei and his surgical colleagues in 1967. During this procedure a small segment of duodenum was included in pancreas transplantation.

Over the next 20 years, when larger segments were used in order to restore oral nutrition, there was universal failure. The main problems were rejection and infection. With the introduction of immunosuppressants, azathioprine in the late 1960s and ciclosporin in the late 1970s, intestinal transplantation was still out of reach.

In the 1980s Grant and colleagues successfully transplanted liver and intestine and achieved long-term survival and oral nutrition using ciclosporin. With the introduction of tacrolimus, transplantation became increasingly successful. Now, intestinal transplantation has become a routine clinical procedure for selected patients. Over the last 10 years patient survival figures have improved considerably and are now approaching those receiving organs such as liver, lung and heart. Patient selection has improved and immunosuppression has been enhanced by the introduction of lymphocyte modulating antibody therapy combined with less potent maintenance immunosuppression.

The indications for intestinal transplantation are:

- Life-threatening complications of parenteral nutrition
  - severe or progressive liver disease despite all remedial actions
  - recurrent septic episodes
  - lack of central venous access
- Very poor quality of life thought to be correctable by transplantation
- Patients with indications for extensive surgery involving partial or complete evisceration (Wiles et al, 2011).

Patients that unfortunately get to the point of requiring a small bowel transplant can be referred directly to a transplant centre or to an intestinal failure unit. Patients can also be presented for consideration at the National Adult Small Intestinal Transplant forum meetings by any centre. There are three categories within the surgical options for patients with intestinal failure requiring a small bowel transplant. The type of surgery depends on the patients status and anatomical requirement to treat their intestinal failure:

- Isolated intestinal transplantation
- Multivisceral transplantation (including a liver transplant)
- Modified multivisceral transplant (does not include the liver).

The survival rates of patients requiring home parenteral nutrition range between 86–97% at 1 year, 57–83% at 5 years and 43–71% at 10 years (8:9). Survival following intestinal transplantation (any combination of organs including small intestine), as reported by the international registry (which

receives details of >90% of all cases worldwide) is 75% at 1 year and 58% at 5 years, but this survival gap is continuing to close. In the better performing centres (10:11), survival figures approximate to those on home parenteral nutrition, particularly for patients given lymphocyte-depleting induction therapy, whose survival at 1 and 5 years has been reported to be as high as 90% and 70% respectively (Abu-Elmagd et al, 2009).

Considerable advances over the last 20 years have taken intestinal transplantation from the first procedures that provided only short-term success to its current status as a routine therapeutic option for selected patients. Although home parenteral nutrition remains the primary treatment for most patients with intestinal failure, we approach a new era when intestinal transplantation will be considered the primary treatment for most patients. This promises to be cost effective and bring with it better quality of life for patients without reducing their longevity. A key element of success is appropriate timing of referral to a national IF or transplantation centre. All health professionals should be aware of when and how to refer patients, and seek advice early in the management of the more complex patients.

BJN

*Conflict of interest: This article was sponsored by ConvaTec*

*To complete this module, contact ConvaTec on 0800282 254 (UK) 1800 721 721 (ROI) or email [stoma.webcare@convatec.com](mailto:stoma.webcare@convatec.com) to get the module workbook. Your CPD certificate will be sent to you directly.*

- Abu-Elmagd KM, Costa G, Bond GJ et al (2009) Five hundred intestinal and multivisceral transplantations at a single center: major advances with new challenges. *Ann Surg* **250**(4): 567–81
- Berry SM, Fischer JE (1996) Classification and pathophysiology of enterocutaneous fistula. *Surg Clin North Am* **76**(5): 1009–18
- Burch J (2004) Stoma Care. Blackwell Publishing, Oxford
- Carlson GL (2003) Surgical management of intestinal failure. *Proc Nutr Soc* **62**(3): 711–8
- Fischer JE (1983) The pathophysiology of enterocutaneous fistula. *World J Surg* **7**(4): 446–50
- Fleming CR, Remington M (1981) 'Intestinal failure'. In: Hill GL (ed) *Nutrition and the Surgical Patient*. Churchill Livingstone, New York: 219–35
- Forbes A (2007) Global guidelines for nutrition support. *Lancet* **370**(9603): 1906
- Gabe S (2013) Managing high-output stomas: module 2 of 3. *Br J Nurs* **22**(16): S18–20
- Gabe S, Slater R (2013) Managing high-output stomas: module 1 of 3. *Br J Nurs* **22**(5): S26–30
- Ham M, Horton K, Kaunitz J (2007) Fistuloclysis: Case Report and Literature Review. *Nutr Clin Pract* **22**: 553–7
- Jones BJM (1986) Enteral Feeding: techniques of administration. *Gut* **27**(Suppl 1): 47–50
- Levy E, Frileux P, Sandrucci S et al (1988) Continuous enteral nutrition during the early adaptive stage of the short bowel syndrome. *Br J Surg* **75**(6): 549–53
- Nightingale JM (2001) *Intestinal failure*. Greenwich Medical Media Ltd, London
- Nightingale JM (2003) The medical management of intestinal failure: methods to reduce the severity. *Proc Nutr Soc* **62**(3): 703–10
- Scripcariu V, Carlson G, Bancewicz J, Irving MH, Scott NA (1994) Reconstructive abdominal operations after laparotomy and multiple repeat laparotomies for severe intra-abdominal infection. *Br J Surg* **81**(10): 1475–8
- Sica J, Burch J (2007) Management of intestinal failure and high-output stomas. *Br J Nurs* **16**(13): 772–77
- Teubner A, Morrison K, Ravishankar HR, Anderson ID, Scott NA, Carlson GL (2004) Fistuloclysis can successfully replace parenteral feeding in the nutritional support of patients with enterocutaneous fistula. *Br J Surg* **91**(5): 625–31
- Wiles A, Gabe S, Middleton SJ (2011) Small bowel transplantation – the latest developments. *Medicine* **39**(3): 183–9

